

Evaluation of projection-based augmented reality technique in cerebral catheter procedures

The usability of a projection-based augmented reality technique

Ahmet Gökyar¹, Sinan Bahadır¹, Cengiz Çokluk²

¹Department of Neurosurgery, Medical Faculty of Amasya University, Amasya

²Department of Neurosurgery, Medical Faculty of Ondokuz Mayıs University, Samsun/Turkey

Abstract

Aim: In this experimental study, we evaluated the usability of a projection-based augmented reality technique, achieved by projecting cranial computerized tomography images from an external image source onto cattle skull, for localization of the frontal horn of the lateral ventricle and placing ventricular catheter. **Materials and Methods:** Eleven skulls obtained from fresh cattle cadavers were used for this experimental study. Axial computerized tomography images including the lateral ventricle sections were projected on the cattle skull over the superior surface. Puncturing needle was inserted from the surface into the frontal horn of the right lateral ventricle with the guidance of projection-based augmented reality images. Placements of catheters were evaluated by computerized tomography.

Results: In two (18.18%) of the samples location of the catheter tip was found in unfavorable location. Acceptable results were achieved in six samples (54.54%). In the remaining three (27.28%) of the samples, location of the needle tip was found in ideal location. Successful placement of ventricular catheters was achieved in nine (81.82%) of the experimental materials using image projecting augmented reality technique.

Discussion: The results of this study revealed that placement of cerebral catheters with the guidance of projection-based augmented reality is a safe, fast and simple procedure. This procedure provides the accurate location of the selected target seated within the brain parenchyma. This procedure may be used in similar kind of brain operations in the location of the lesion following more detailed and further investigations.

Keywords

Brain surgery; Localization; Augmented reality; Projection; Neuronavigation

DOI: 10.4328/ACAM.20165 Received: 2020-03-17 Accepted: 2020-04-17 Published Online: 2020-04-25 Printed: 2020-11-01 Ann Clin Anal Med 2020;11(6):630-633

Corresponding Author: Ahmet Gökyar, Department of Neurosurgery, Medical Faculty of Amasya University, Amasya, Turkey.

E-mail: drgokyar@gmail.com / ahmet.gokyar@amasya.edu.tr GSM: +90 5324656498 P: +90 3582184000 F: +90 3582180104

Corresponding Author ORCID ID: <https://orcid.org/0000-0003-1942-587X>

Introduction

Navigation systems in surgery are in use for over several decades [1]. It was rapidly adopted in neurosurgery where prevention of any injury to normal structures has the utmost importance. As of today, several advanced and complex navigational systems are available. However, these systems are so expensive that not every institute can afford one.

Hydrocephalus has a prevalence of 88/100,000 in children, 11/100,000 in adults and 175/100,000 in elderly. There is no effective medical treatment for hydrocephalus. So, surgical interventions, particularly ventricular shunt systems, remain as major treatment option [2]. Ventricular catheter insertion depends on surgeon's experience. Each unsuccessful trial leads to additional neural damage. Despite all care taken during surgery, malposition occurs in 8% of shunt procedures and makes additional surgery mandatory [3]. Shunt insertion is a procedure which may benefit from navigational systems. However, hydrocephalus incidence is higher in low and middle-income countries where complex navigation systems are out of reach for most neurosurgeons [2].

The integration of virtual images onto real-world surface, known as augmented reality (AR), also found its way into surgical field. Projection of 3D constructed images onto patient's body was successfully performed in thorax surgery, neurosurgery and dental surgery [4-6].

In this study, we evaluated the effectiveness of projection-based AR (PB-AR) in ventricular shunt insertion where the location of the lateral ventricle frontal horn was superficially detected on the brain surface by projecting computerized tomography images.

Material and Methods

Eleven fresh cadaveric cattle skulls were used for this experimental study. All the skulls obtained from cattle which are sacrificed commercially for other purposes. Since no living animal was sacrificed for this experiment, no ethical committee approval is required.

The experiment procedure was schematized in Figure 1. The cadaveric cattle skulls were scanned by computerized tomography in rostral to caudal direction with 5mm slice thickness to achieve axial images. All axial sections were recorded in DICOM file format and transferred to a commercially available laptop computer (Figure 2). The original magnification legends were kept visible. A commercially available digital projector (LG, PH300-GL, Korea) connected to computer was secured to a position just above the specimen. Following this step, the axial section image corresponding to the lateral ventricle section was projected on the superior surface of the cattle skull. Orbital cavities and lateral borders of nasal bones were used as reference points to fit the CT image to the cattle skull. Also, the projected image was magnified until the magnification legend matched a real ruler. The target was designated as the frontal horn of the right lateral ventricle. A burr-hole was opened by using high-speed surgical drill (Midas-Rex Legend EHS Stylus, US) 1 cm anterior to the coronal suture and 1cm lateral to the midline. The ventricular catheter was inserted from the surface to the frontal horn of the lateral ventricle of the cattle skull according to the guidance of AR

images (Figure 3a). The catheter was fixed over the skull bone surface. An axial CT scan was performed to check the location of the catheter tip (Figure 3b).

Outcomes were assessed by the location of catheter tip respective to the lateral ventricle. A totally intraventricular placement is considered as "ideal". Catheter tip located adjacent to the lateral border of the ventricle is considered as "acceptable". The rest are considered as "unfavorable".

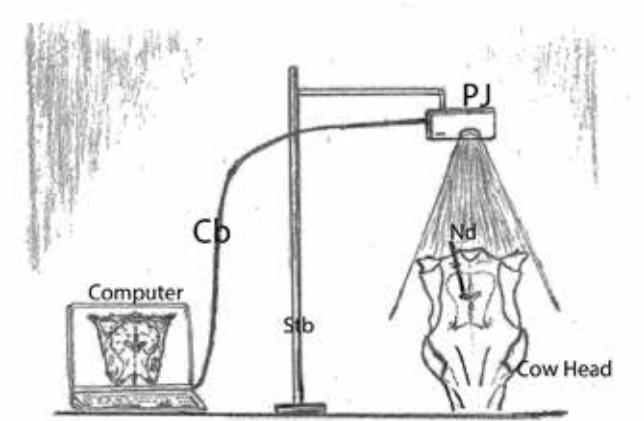


Figure 1. In this figure, the experimental procedure was schematized. The virtual image was projected over the specimen to localize the frontal horn of the lateral ventricle before inserting the catheter. (Pj: projector, Nd: needle, Stb: stabilizer, Cb: cable).

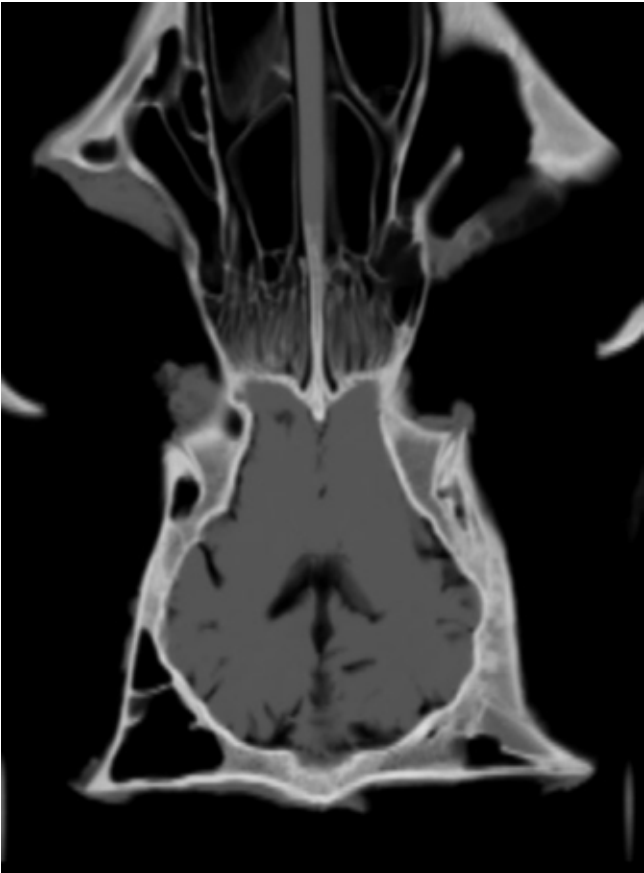


Figure 2. This figure shows an axial CT scan of the brain. The image was transferred from computer to projector and projected over subjects during entry to the frontal horn of lateral ventricle.

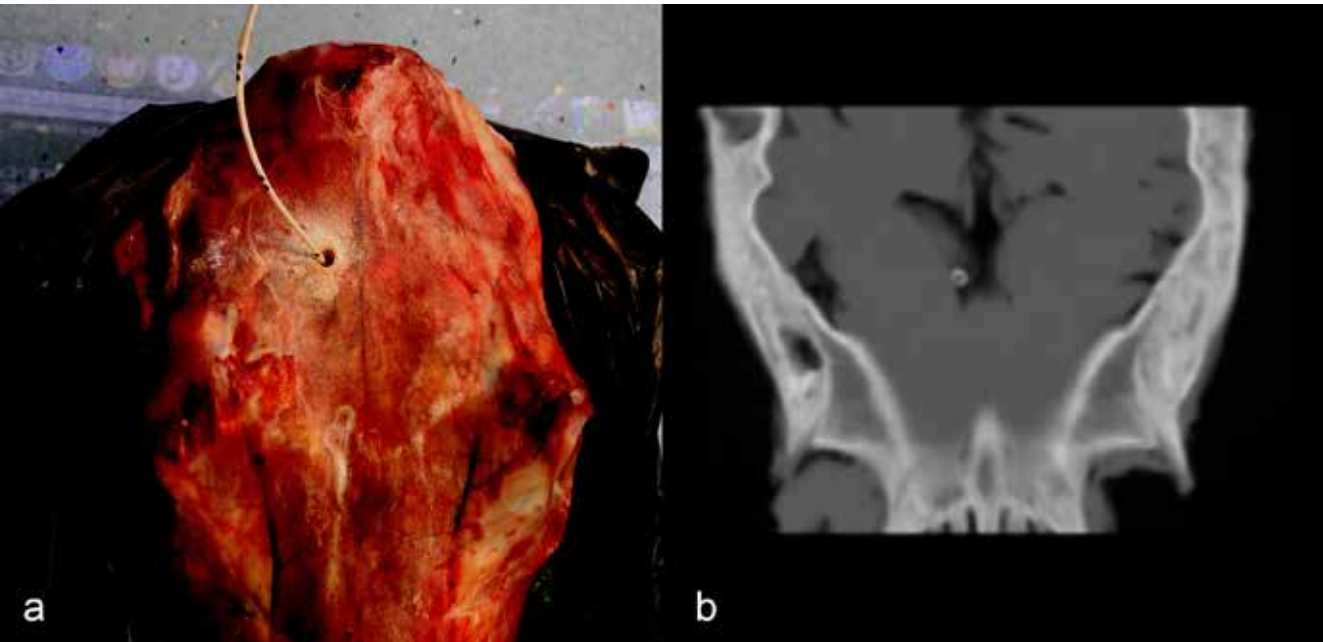


Figure 3. a) This figure shows the subject for the experimental procedure. In this figure the axial CT image of the brain was projected over the skull surface. b) Axial CT section image of the brain along the catheter shows the correct location of the needle.

Results

Of eleven cattle skulls, in two (18.18%), the needle placement was unfavorable. Acceptable results were achieved in six (54.54%) of the specimens. In the remaining three (27.28%), needle placement was ideal. Successful results (good and acceptable) were achieved in nine (81.82%) of the subjects using PB-AR technique in fresh cadaveric cattle brains. The results for each specimen are summarized in Table 1.

Table 1. Position of ventricular catheters regarding lateral ventricle wall

Specimen	Deviation from lateral ventricle wall	Outcome
1	2mm, lateral	Unfavorable
2	3mm, medial	Good
3	9mm, lateral	Unfavorable
4	0mm, medial	Acceptable
5	2mm, medial	Good
6	0mm, lateral	Acceptable
7	0mm, lateral	Acceptable
8	1mm, medial	Good
9	0mm, lateral	Acceptable
10	0mm, medial	Acceptable
11	0mm, lateral	Acceptable

Discussion

Our study demonstrated that inserting a ventricular catheter guided by AR application is a viable technique in cattle suggesting it can also be applied in clinical situations. Malposition in our study was 18.18% which is higher than in the literature [3]. In a real shunt procedure, ventricular entry is determined by the efflux of cerebrospinal fluid (CSF) through catheter. If no CSF exits the catheter, another entry is performed to establish ventricular entry. However, an 8% rate of malposition stated in the literature only covers postsurgical evaluations and it is

highly possible that failure to enter intraventricular space at first attempt is much higher. Moreover, ventricles of hydrocephalus patients are larger than normal making it easier to enter and masking any misdirection. We believe the discrepancy in the malposition rate of our study with the literature result from the number of entry attempts and enlargement of ventricles in clinical cases.

We used a cattle skull for our study. It had some advantages over other animal models and clinical experiment. Cattle brain, and thus ventricles are closer to the human brain in size compared to other animals used in experiments allowing the use of readily available ventricular catheters. Another advantage is, since cattle are slaughtered for needs of society routinely, no animal had to be sacrificed just for the experiment. All used skulls were obtained from already slaughtered cattle. However, the model also has its disadvantages. Apart from being bigger and heavier, human brain is also rounder when compared to cattle brain. A cattle’s brain is elongated in shape, whereas a human brain is rounded. Still, location of interhemispheric sulcus and characteristic features of ventricles are similar in human and cattle brain making it is a suitable model.

Surgical procedures, especially neurosurgical procedures require precise localization to achieve minimal damage to surrounding structures [7], so that neurosurgery became one of the earliest adopters of image guidance to increase surgical accuracy and reduce the size of craniotomy [1]. Advanced neuro-navigation systems have significant cost implications in underdeveloped and developing countries. Relying on anatomical landmarks is also prone to error. In areas with suitable accuracy and minimal movement, AR techniques may reduce the injury risk [8,9]. AR techniques, unlike expensive and state-of-the-art navigational systems, do not require the surgeon to constantly gazing between the surgical field and images on navigation monitors which can cause surgical errors [5,6]. On the contrary, AR provides an enormous ergonomic improvement where the surgeon can see anatomical structures on the skin of the patient

[5]. The most basic and affordable method is superimposing a computer-generated image on the surgical area through a video projector. Another option is using head-mounted hardware which require additional utilities. They may also put tension on surgeon's neck muscles [9].

Besides providing the surgeon the chance to see pathology related anatomy directly on the patient skin with a significantly low cost, AR has additional advantages. AR is a noninvasive procedure. Though an experienced surgeon can select appropriate positions, catheter direction in hydrocephalus case without any need for guidance, being able to see patient's real anatomy facilitates this process. Finally, it could serve as a valuable training tool where it helps residents understand spatial relationships during procedure [4,9].

This study is not deprived of limitations. First of all, this is a descriptive study. We did not include any control group to compare successful ventricular catheter placement with or without AR since none of the researchers have any practice in placing ventricular catheters in the skull brain, which is necessary to obtain comparable results. We aimed to evaluate if AR is applicable or not in ventricular catheter placement. Nevertheless, our rates are comparable to literature data. As discussed above, though cattle and human brains share some similarities, they are not exactly the same. Another problem is registration of the projected image on the sample. Though we used simple landmarks and consider overall registration fairly good, the use of fiducial markers may improve accuracy. One possible argument for use of AR may be the distortion resulting from projecting a 2D image onto a 3D surface. The upper surface of the cattle skull is pretty straight and our target area was close to the midline, yet we did not analyze distortion on the images. However, a study investigating distortion aspect of AR on a human head model found that projection of sagittal and axial images on lateral and superior surfaces of head did not distort more than 2mm except for the edges. This rate of distortion is highly sufficient for ventricular shunt procedures. Finally, we did not perform any lateral projection to visualize ventricle depth from the surface. Ventricle depth is calculated via CT scans of subjects.

Conclusion

Our study suggests that placing an intraventricular catheter with the help of AR is a feasible technique. Although the technique needs evaluation through a controlled study and needs some improvement regarding image accuracy, due to its low cost and ease of use it could be valuable in achieving optimum intraventricular catheter placement as part of a shunt system or external ventricular drainage system in low and middle-income countries.

Scientific Responsibility Statement

The authors declare that they are responsible for the article's scientific content including study design, data collection, analysis and interpretation, writing, some of the main line, or all of the preparation and scientific review of the contents and approval of the final version of the article.

Animal and human rights statement

All procedures performed in this study were in accordance with the ethical standards of the institutional and/or national research committee and with the 1964 Helsinki declaration and its later amendments or comparable ethical standards. No animal or human studies were carried out by the authors for this article.

Funding: None

Conflict of interest

None of the authors received any type of financial support that could be considered potential conflict of interest regarding the manuscript or its submission.

References

1. Edwards PJ, Hawkes DJ, Hill DLG, Jewell D, Spink R, Strong A, et al. Augmentation of Reality Using an Operating Microscope for Otolaryngology and Neurosurgical Guidance. *J Image Guid Surg*. 1995;1(3):172-8.
2. Isaacs AM, Riva-Cambrin J, Yavin D, Hockley A, Pringsheim TM, Jette N, et al. Age-specific global epidemiology of hydrocephalus: Systematic review, metanalysis and global birth surveillance. *PLoS One*. 2018;13(10):e0204926. DOI: 10.1371/journal.pone.0204926
3. Feletti A, d'Avella D, Wikkelsso C, Klinge P, Hellström P, Tans J, et al. Ventriculoperitoneal Shunt Complications in the European Idiopathic Normal Pressure Hydrocephalus Multicenter Study. *Oper Neurosurg (Hagerstown)*. 2019;17(1):97-102.
4. Oizumi H, Kato H, Watarai H, Sadahiro M. Three-dimensional computed tomography image overlay facilitates thoracoscopic trocar placement. *J Thorac Cardiovasc Surg*. 2013;146(3):720-1.
5. Tabrizi LB, Mahvash M. Augmented reality-guided neurosurgery: accuracy and intraoperative application of an image projection technique. *J Neurosurg*. 2015;123(1):206-11.
6. Suenaga H, Tran HH, Liao H, Masamune K, Dohi T, Hoshi K, et al. Vision-based markerless registration using stereo vision and an augmented reality surgical navigation system: a pilot study. *BMC Med Imaging*. 2015;15:51.
7. Grimson E, Leventon M, Ettinger G, Chabrierie A, Ozlen F, Nakajima S, et al. Clinical Experience with a High Precision Image-guided Neurosurgery System. In: Wells WM, Colchester A, Delp S, editors. *First International Conference on Medical Image Computing and Computer-Assisted Intervention — MICCAI'98*; Massachusetts, USA. Heidelberg: Springer; 1998; 67-73.
8. Vakharia NN, Paraskevopoulos D, Lang J, Vakharia VN. The Assessment of Distortion in Neurosurgical Image Overlay Projection. *Surg Innov*. 2016;23(1):14-22.
9. Vávra P, Roman J, Zonča P, et al. Recent Development of Augmented Reality in Surgery: A Review. *J Healthc Eng*. 2017;2017. DOI: 10.1155/2017/4574172.

How to cite this article:

Ahmet Gökyar, Sinan Bahadır, Cengiz Çokluk. Evaluation of projection-based augmented reality technique in cerebral catheter procedures. *Ann Clin Anal Med* 2020;11(6):630-633